

# Intervention

Your portal to modern medicine



**Paediatric Interventional  
Radiology**

**Patients Vote with  
their Wallets**

**Economy Class Syndrome –  
an Economic Nightmare**

## **Venous Interventions**

**Varicose Veins and  
Interventional Radiology**

**Venous Disorders:  
Widespread and Costly**

Interviews . Reports . Case Studies  
from the world of image-guided  
minimally invasive therapy

[www.intervention-iq.org](http://www.intervention-iq.org)

# Minimally invasive image-guided medicine makes waves in **HOSPITALS** across Europe

- ⊙ **Superior Service**  
Promoting Innovative & Multidisciplinary Medicine
- ⊙ **Improved Performance**  
Cost-Effective Treatments & Shorter Hospital Stays
- ⊙ **Increased Patient Demand**  
Reduced Risk, Pain & Recovery Times

I n t e r v e n t i o n a l   Q u a r t e r

**[www.intervention-iq.org](http://www.intervention-iq.org)**  
**Many avenues. One address.**

## A Welcome from the Editor



Dear Readers,

It gives me great pleasure to present this edition of Intervention IQ, with venous interventions as the leading theme. When we talk of venous disorders, many people might think only of unsightly varicose veins and underestimate them as merely a cosmetic problem. However, visible varicose veins are just one sign of chronic venous insufficiency; a disease state that has serious implications for long-term health and quality of life.

As well as offering treatments for manifestations of chronic venous disease, interventional radiology (IR) is making its presence felt in the treatment of acute venous problems, namely deep vein thrombosis.

The high prevalence of these disorders means that a great many individual lives are touched. Furthermore, health-care institutions and societies as a whole must come to terms with the costs of venous disease. Intervention IQ looks at the vitally important work that interventional radiologists do each day, examining how these efforts contribute to the multidisciplinary team and result in excellent outcomes for patients and hospitals.

Venous interventions represents an exciting field to be involved in, where minimally invasive image-guided techniques are already well established yet new developments are always on the horizon. Ongoing improvement and advancing technologies continue to provide us with the tools to make a real difference to patients' lives. In this edition we take a look at the development of prosthetic venous valves as an example of IR pushing back the boundaries of modern medicine.

This innovative spirit has always been characteristic of IR and the story of the milestone development of catheter-delivered vena cava filters is recounted in our Early Days feature. Further supporting articles look at the unique challenges of paediatric IR and how an understanding of health economics is increasingly important to us all.

I sincerely hope you enjoy reading this issue and that you find our overview of IR's role in venous interventions both informative and inspirational.

A handwritten signature in black ink, appearing to read 'Jim A. Reekers'.

Jim A. Reekers  
Editor-in-Chief

## General Information

**Interventional Quarter is published three times a year. To add an address to the mailing list, please contact [info@intervention-iq.org](mailto:info@intervention-iq.org) or refer to [www.intervention-iq.org](http://www.intervention-iq.org).**

### Editorial Office

Neutorgasse 9/8  
AT-1010 Vienna, Austria  
Tel: +43 (0)1 904 2003  
Fax: +43 (0)1 904 2003 30  
E-mail: [info@intervention-iq.org](mailto:info@intervention-iq.org)  
[www.intervention-iq.org](http://www.intervention-iq.org)

ISSN: 2075-5813

Cover Image © dreamstime.com/Piotr Marcinski

© All rights reserved by  
Next Publishing Research & Media / 2012  
The reproduction of whole or parts of articles is prohibited without the consent of the Publisher. The Publisher retains the right to republish all contributions and submitted materials via the internet and other media.

The Publisher, Editor-in-Chief, Editorial Team and their respective employees make every effort to ensure that no inaccurate or misleading data, opinion or statement appears in this publication. Contributed articles do not necessarily reflect the views of Interventional Quarter. This is not a peer-reviewed journal, and professional medical advice should always be sought before following or discontinuing any course of treatment. Therefore, the Publisher, Editor-in-Chief, Editorial Team and their respective employees accept no liability for the consequences of any such inaccurate or misleading data, opinions or statements.

### Editor-in-Chief

Prof. Jim A. Reekers, EBIR (Amsterdam, Netherlands)

### Managing Editor

Nadja Alomar

### Editorial Team

Robert Bauer, Ciara Madden, Adam McLean, Tochi Ugbor

### Our thanks to the Contributors

Prof. Lieven Annemans (Ghent, Belgium)  
Prof. Christoph Binkert, EBIR (Winterthur, Switzerland)  
Prof. Elias Brountzos, EBIR (Athens, Greece)  
Dr. Anne-Marie Cahill (Philadelphia, USA)  
Dr. Michael Darcy (St. Louis, USA)  
Prof. Rolf Günther (Aachen, Germany)  
Dr. Maccon Keane (Galway, Ireland)  
Dr. Sanjoy Kundu (Toronto, Canada)  
Dr. Kieran McBride (Fife, UK)  
Dr. Sanjay Nadkarni (Perth, Australia)  
Dr. Levent Oguzkurt, EBIR (Adana, Turkey)  
Dr. Gerard O'Sullivan, EBIR (Galway, Ireland)  
Prof. Dusan Pavčnik (Portland, USA)  
Dr. Luc Stockx (Genk, Belgium)  
Dr. David West, EBIR (Stoke-on-Trent, UK)

### Graphical Design

LOOP. ENTERPRISES media EU / Austria  
[www.loop-enterprises.com](http://www.loop-enterprises.com)



## An invitation to our readers

**IQ is your magazine, and we would welcome your views and your news. Readers who wish to comment on any of the issues raised (or who would like to raise any of their own) are most welcome to submit letters to the Editor. Likewise, if you have any promotions, awards, honorary lectures or other tit-bits you'd like to share with the interventional community, please send them to us by post or by email.**

**We look forward to hearing from you!**  
IQ Editorial Team

Email: [info@intervention-iq.org](mailto:info@intervention-iq.org)  
Write to: Neutorgasse 9/8, AT-1010 Vienna, Austria



---

## Contents

- 4 Venous Interventions**  
*A look at venous disorders and IR's role in treating them*
- 14 Varicose Vein Treatment the IR way**  
*Expert ultrasonography and endovascular techniques guarantee excellence in Turkey*
- 16 Voting With Their Wallets**  
*Why patients are paying privately to attend the Scottish Vein Centre*
- 18 Worldview**  
*IQ takes a look at vein clinics around the world*
- 20 Turning the Tide of Venous Insufficiency**  
*How bioprosthetic venous valves may prove a breakthrough for IRs*
- 22 Economy Class Syndrome – an Economic Nightmare**  
*Dealing with deep vein thrombosis*
- 24 Venous Disorders: widespread and costly**  
*Summing up the macroeconomic implications of venous disorders in Germany*
- 25 Venous Trials and Registries**  
*A selection of current trials and registries investigating venous interventions*
- 26 Weighing Up the Benefits of IR**  
*Health economist Lieven Annemans on the delicate balance between cost and effect*
- 28 Paediatric IR – tailor-made solutions for tiny patients**  
*A look at IR's role at the Children's Hospital of Philadelphia*
- 30 Trials and Registries**  
*A selection of current trials and registries*
- 32 The Early Days of IR**  
*Prof. Rolf Günther talks to us about his breakthrough IVC filter*



# Venous Interventions

**Our veins form a complex network that runs through our entire body. Continually returning deoxygenated blood to the lungs, they form an integral part of our wellbeing. With over 90% of the population suffering from some form of venous disorder, there is huge demand for therapies that can restore healthy vein function – and interventional radiology (IR) is leading the field.**

## Circulation

When everything is running smoothly, most people don't give their circulation much thought. But silently and out of sight something impressive is happening.

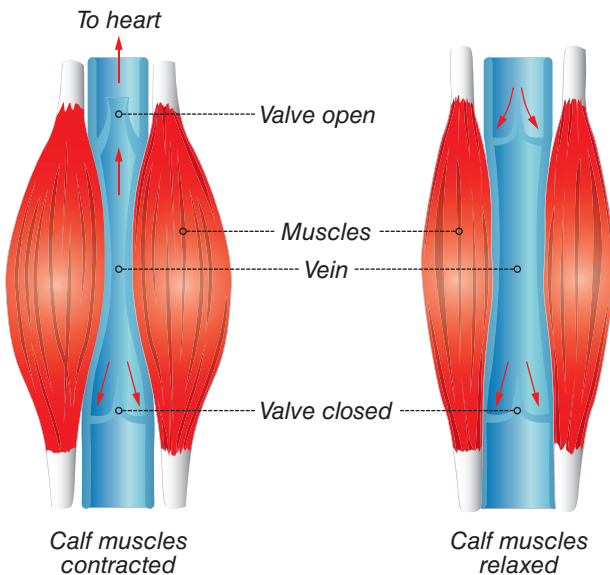
The heart pumps the equivalent of approximately 7,000 litres of blood around the body each day. Blood is first sent along the arteries, delivering oxygen from the lungs to the other organs and tissues. Then it is the job of the veins to convey the de-oxygenated blood from every corner of the body back to the heart, and the cycle starts again.

## Veins: a one-way system

By the time the blood has reached the veins, the pumping force of the heart is not so strongly felt. Furthermore, this part of the circulatory system must do most of its work against the force gravity; this is especially significant in the long veins of the legs.

The position and structure of veins help them to guide the large volumes of blood back up towards the heart.

- Vessel elasticity: vein walls help blood to return in the direction of the heart
- One-way valves: prevent backflow of blood in the wrong direction
- Leg muscle pump: also known as the peripheral heart. As the calf muscles contract, they squeeze the leg veins, helping to push the blood upwards towards the heart



As the muscles of the lower leg contract, for example when walking, the blood in the veins is pushed upwards towards the heart. The valves in the veins are opened by the pressure of the blood moving in the right direction. When the muscles relax, the valves close, preventing the backflow and pooling of blood.

## What can go wrong

Venous problems can arise from inappropriate blood clotting (**thrombosis**) or false connections between blood vessels (**malformations**). A disturbance in the efficient functioning of the veins can be due to a loss of tone or damage to the vein walls or valves.

**Venous insufficiency** describes the state when veins do not effectively perform their role of returning the blood to the heart, often due to weakened and leaky valves. Blood pools in the venous system, the veins swell and bulge outwards (varicose veins) and a range of symptoms can follow.

Venous disorders are often connected and do not necessarily occur in isolation (see page 6).

## Only a cosmetic concern?

Visible veins beneath the skin can be a serious burden for some people, having a notable impact on quality of life and limiting social and recreational activities. But varicose veins are not always merely a cosmetic problem and a range of further symptoms can ensue (see page 6).

The large number of people affected means that overall costs to healthcare systems are high and the wider economy suffers from the associated morbidity.

## How IR can help

Using modern image guidance, interventional radiologists are able to provide minimally invasive treatment solutions for many venous disorders.

The great strength of interventional radiology (IR) is its ability to take the same imaging techniques that allow accurate diagnosis and use them also to guide treatments. These treatments generally require less anaesthesia, shorter hospital stays, a shorter recovery period and result in fewer complications.

The highly refined skills of interventional radiologists also enable them to provide elegant solutions to gaining venous access in the clinic, allowing haemodialysis or the rapid delivery of medication and nourishment. This has life-saving consequences for a great many patients.



## The vicious venous cycle

CVI and varicose veins (a form of CVI) have slightly different origins, but then follow the same path.

How Chronic Venous Insufficiency (CVI) can progress:

**Thrombophlebitis** (blood clots in the vein)  
or  
Phlebitis (an inflammation of the vein)  
can cause structural damage

CVI (veins are not able to pump sufficient deoxygenated blood back to the heart)

How varicose veins can progress (a specific form of CVI):

Faulty valves – can be genetic, or caused by hormonal/mechanical damage or strain on the legs (e.g. high heels; standing/sitting for regular extended periods)

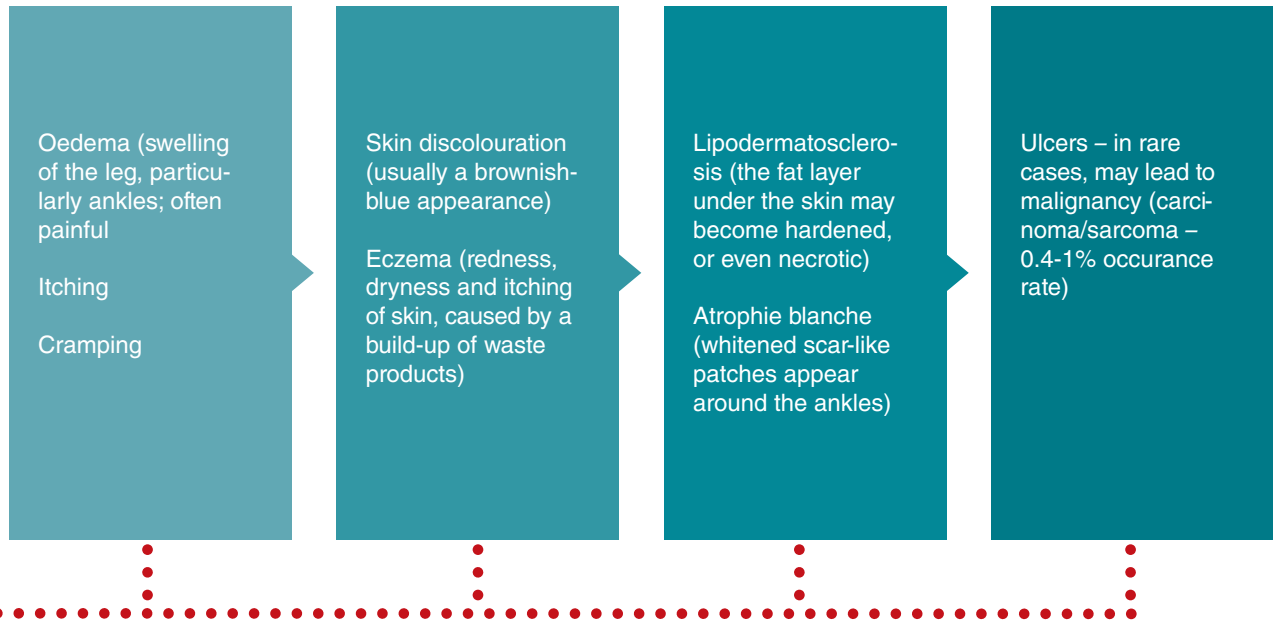
Telangiectasia (spider veins)  
Reticular veins (blue veins which stand out)

Varicose veins – unable to flow upwards, the blood pools in the vein, distending and stretching it, causing it to appear knotted

Using modern image guidance, interventional radiologists are able to provide minimally invasive treatment solutions for many venous disorders



At this stage of the disease process, these symptoms can cause **Thrombophlebitis** - blood clots that form within vein – mostly superficial, but can extend to deep veins (see page 22)



Varicose veins occur most commonly in the legs, which are furthest from the heart and subject to the greatest gravitational strains. But faulty valves also manifest as:

- **Varicoceles** in men: an enlargement of the vein in the scrotum, which can lead to pain, swelling, or shrinking of the testes
- **Pelvic congestion syndrome (PCS)** in women: where the veins of the pelvic region become distended and painful. This is often related to the strains of pregnancy and labour (see IQ #4 for more information)

Interestingly, women are generally more susceptible to venous problems, primarily because the hormone oestrogen weakens the vein walls.

(IR) treatments generally require less anaesthesia, shorter hospital stays, a shorter recovery period and result in fewer complications

Read on to find out more



## Radiofrequency ablation



Prof. Christoph A. Binkert, MD, MBA, Director of the Institute of Radiology and Chairman of Diagnostic and Interventional Radiology, Winterthur Kantonsspital, CH

### The treatment

Radiofrequency (RF) ablation is one of the common ways to treat symptomatic varicose veins by applying endovenous heat.

With the latest technology a catheter with an RF tip is inserted into the varicose vein and advanced to where the treatment should begin, which is typically at the groin level. The RF tip heats each segment to 120°C for 20 seconds, as the catheter is carefully pulled back segment by segment.

As it is heated the injured vein will close shut and no longer be able to cause troublesome symptoms.

In order to protect the surrounding healthy tissue a large amount of local anaesthetic is injected around the vein (tumescent anaesthesia), this absorbs excess heat so burning is avoided.

### Ablation methods compared

RF and laser treatments have shown very similar results. One advantage of RF is that the therapy is more standardised as the technique requires the catheter to be pulled back segment by segment every 20 seconds. Laser ablation involves a continuous pull back during the procedure: this will vary with each physician.

Another advantage is that the RF therapy seems to give rise to less postprocedural pain and bruising when compared to bare tip laser fibres. However, this advantage may be balanced when covered laser fibre tips and different wave lengths are used.

### Interdisciplinary care

Patients with symptomatic varicose veins are examined at our interdisciplinary vascular centre, in which interventional radiology (IR), vascular surgery and angiology work together.

To begin with, a physician of any one of these specialties examines the patient. A duplex ultrasound is a vital part of the examination, in order to reliably diagnose and locate the insufficient varicose vein(s) causing the symptoms.

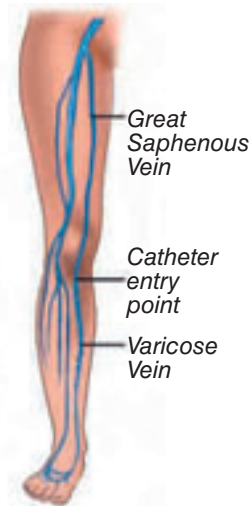
RF therapy can be applied in most cases except when varicose veins are very tortuous or the diseased vein segments are very short (less than 10cm). In these circumstances surgical therapy is more suitable.

### The results

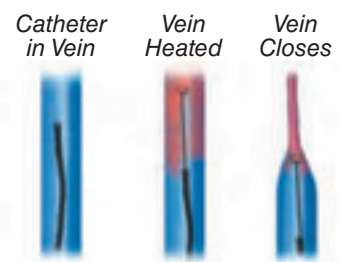
RF therapy of varicose veins is a safe and effective procedure with success rates of 90% or higher at two years.

Symptoms disappear typically within a few weeks and serious complications are extremely rare. The most likely problem is aching pain and bruising for a few days. Some staining of the treated vein can occur although this discoloration has no clinical impact. In rare cases the nerve which runs alongside the vein can be damaged by the heat. This sounds more dramatic than it is because typically the problem is only a sensory deficit around the ankle which is likely to recover over the following months. Motor function is hardly ever impaired.

Superficial Veins of the leg



Vein Ablation



Reprinted with permission of the Society of Interventional Radiology © 2004-12, www.SIRweb.org. All rights reserved.



Thorough follow-up is an essential part of clinical care: Prof. Binkert takes time to sit down with the patient in his office. Image courtesy of Prof. C. Binkert.

## Patient satisfaction

The vast majority of the treated patients are very pleased with the procedure. Patients like the fact that RF therapy is an outpatient treatment with only local anaesthesia needed. They are also very happy and sometimes even surprised that there is little or no recovery time, minimal or no pain and a good cosmetic outcome.

Unfortunately, RF and laser vein therapies are generally not reimbursed by insurance companies in many European countries. Therefore, the treatment has to be paid for by the patient. Efforts to overcome the reimbursement issues are being made.

## Patient's point of view

Ms. Sonja Budja, a patient of Prof. Binkert, shares her experience of how she found RF therapy a convenient and effective treatment for symptomatic varicose veins:

*"The leg that was affected felt uncomfortably heavy and the calf was discoloured and red. I feared the development of an ulcer.*

*"I had already had a vein-stripping operation done on the other leg 20 years ago and I can remember how the*

*operation was quite invasive. I needed spinal anaesthesia and had to stay in hospital for three days. This time around, I looked for a less invasive treatment option that wouldn't require me to stay in hospital or have strong anaesthesia.*

*"The [endovenous RF therapy] I then had six weeks ago was very tolerable. I could barely feel the pinpricks of the needles. The atmosphere was relaxed and so the procedure went by very quickly. I was most impressed that I left home at 14:30 and returned at 17:30, able to walk without any significant pain!*

*"My recovery went very smoothly and I returned to my normal daily routine the next day. I was able to run the household as normal, doing the cooking, cleaning and even the laundry. From the second day after the procedure I was able to go for walks for an hour or so at a time.*

*"I am very happy with the result of the treatment. The heaviness and most of the redness and discoloration have disappeared and I am in no pain. The newer [IR] treatment is an improvement over the surgery which I had on the other leg. I would recommend this treatment to everyone."*

*With very special thanks to Sonja Budja*



## Laser ablation

### The treatment

Laser ablation (also called endovenous laser treatment or ELT/EVLT) is very similar to radiofrequency (RF) ablation: by applying heat from within, the malfunctioning vein can be sealed off.

In a similar manner to RF ablation, a very thin laser fibre is inserted into the vein under local anaesthetic. Once in place, the laser is switched on and slowly withdrawn down the vein. The heat literally melts the vein shut, stopping blood flowing through it.

**Dr. David West, who runs a number of successful vein clinics throughout England, explains how laser ablation is performed, and what advantages it offers.**

*“The key to a successful treatment is imaging. It’s essential to accurately map the anatomy and physiology of the veins you intend to treat – no matter what treatment you intend to use. The best method of doing this is colour duplex ultrasound scanning. A simple handheld Doppler examination is just not good enough. You may achieve short-term success, but the problem will recur and get worse.*

*“Laser ablation itself must be carried out under ultrasound-guidance. If the laser went into a deep vein, it could result in a very nasty deep vein thrombosis (DVT). So it is essential that the performing physician has the required ultrasound skills.”*

### Safety first!

*“The laser works by burning the vein, but there are a number of safety features central to the procedure to ensure that only the malfunctioning vein is affected.*

*“Once the laser fibre is in place, we inject a saline solution alongside the vein, which has a triple safety effect: it causes the distended vein to spasm and hold tightly to the tube inside it, allowing direct contact for maximum heat effect. The saline also cools everything surrounding the vein, as well as pushing all the surrounding nerves and arteries safely out of the way.*

*“The laser fibre itself is fitted with a red light, which is visible through the skin, even on very large patients. This shows you where the laser is, allowing you to ensure that it’s correctly placed. If you don’t see the light, you don’t turn on the laser. Safety is very important to us.”*



### Ablation methods compared

*“Both RF and laser have their own advantages. Laser seems to cause more discomfort and bruising than RF, but the trade-off is that it has a much lower rate of serious complications. Newer laser machines with longer wavelength frequencies are meant to reduce the minor post-procedural discomfort that is associated with laser, so it will be interesting to see the data on that in a few years.*

*“Additionally, about 10% of patients will not be suitable for RF ablation, whereas laser can be used in almost all patients. Both therapies are equally effective.”*

### The beauty of ablation

*“Both ablation procedures offer significant advantages to surgery. Ablation can be performed on an outpatient basis, and entails a much shorter recovery time. With most patients, all refluxing veins can be treated in one session. Each leg takes about 15-30 minutes. The way I run my clinic, consultation, scan, discussion and treatment take 90 minutes in total. After compression stockings and 15 minutes of walking about, patients are free to go home. Six weeks later, I perform follow-up, and if necessary, treat any residual varicosities.”*

***“The recurrence rate is very low: surgery has a recurrence rate of at least 20%, whereas 9 years of data on laser and RF ablation shows a recurrence rate of about 3%. Complication rates for ablation, particularly laser, are practically non-existent.”***



*Dr. West (left) always makes sure his patients are fully informed about the procedure they are about to undergo. Image courtesy of Dr. David West.*



[www.veincentre.com](http://www.veincentre.com)



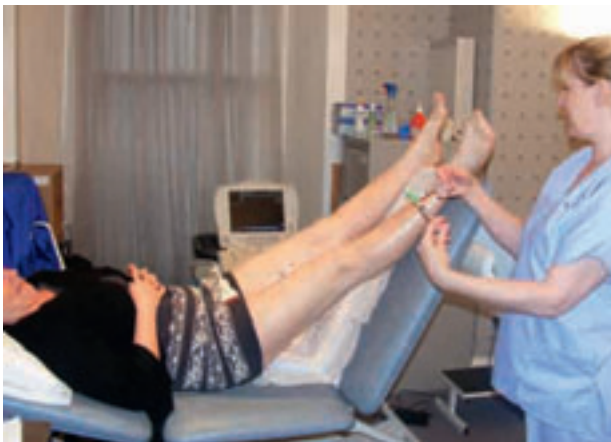## Foam sclerotherapy

A third minimally invasive treatment option is foam sclerotherapy, which acts differently to the thermal ablative techniques. Dr. Kieran McBride, who runs a private vein clinic in Edinburgh, Scotland, talks us through its uses and advantages.

*“There is certainly a role for foam sclerotherapy in treating varicose veins, as well as other venous malformations. While laser has shown to be the most effective of the ablation techniques, ablation is only one part of the procedure. Once the main trunk of the vein has been closed, you often have to follow up and deal with the branch veins – twisty little veins that you can’t put a fibre-optic into.”*

### The treatment

*“The procedure is carried out in a similar manner to ablation, but the active ingredient is different. We use image guidance, usually ultrasound, to place a catheter or needle into the affected vein. We then inject a sclerosant – a detergent that dissolves the lipoproteins in the lining of the vein. So you effectively do a chemical burn, dissolving the vein wall so that blood stops flowing in it. That’s followed with compression therapy, so we put patients into bandaging and stockings to get a better result.”*



*The foam is carefully prepared by mixing a small amount of chemical with air before being injected into the vein. Image courtesy of Dr. Kieran McBride*

### The foam

*“To make the foam, we mix a small amount of chemical with air. A very small amount can actually treat an awful lot of vein, because it expands, pushing the blood out of the way. We then use the transducer and push the foam where we want it to go, and it stays preferentially in those very superficial veins. A small volume may go into the deep veins, but the patient’s leg is elevated, and I usually*

*get them to flex their ankle 20 times and massage their calf afterwards, which washes that small volume of chemical away. So it doesn’t have any direct effect on the deeper veins. The incidence of deep vein thrombosis (DVT) following foam sclerotherapy is actually very small: about 20 in 12,000 shown in a French study.”*

### A safe option

*“The safety record is absolutely impeccable: minor symptoms, such as blurry vision or tightness in their throat, occur in about 5% of patients. Our clinical watchdog in the UK, NICE, has approved it, and I think it offers patients a great alternative to vein stripping.”*

### The attraction of sclerotherapy

*“As I said, this therapy is very valuable for secondary treatment. In my clinic in Fife, we use foam for recurrent veins, which are typically small branches. To surgically re-operate on veins that are recurrent can be quite complicated, and it’s got a recurrence rate itself. Between 20% and 40% of patients that are re-operated on can get complications: wound infections, haematomas, nerve damage, or lymphatic damage. So doing laser and doing foam on these recurrent patients is the logical approach.*

*“Foam sclerotherapy is also valuable as a primary treatment. Injecting foam into the main trunk of a vein has a closure rate of 70-80% – the difficulty here is that those veins are bigger, so you have to use larger volumes of foam, and the complications of foam are related to the volume that you use. But while the closure rates aren’t as impressive as for ablation, there are still many cases where it is eminently more suitable. If a patient presents with very knotted, twisted varicosities, you might not be able to get a straight laser through those bendy veins. That’s where sclerotherapy presents a very attractive option – the foam can spread out to reach all the little nooks and crannies.”*

***“IR treatments for varicosities are the way forward. There’s nobody I’ve ever had to refer to another specialist. There’ll always be something I can offer them. If they’re not suitable for laser or RF ablation, they’ll be suitable for foam sclerotherapy.”***

For more information on Dr. Kieran McBride and the Scottish Vein Centre, please refer to page 16.

## Non-IR treatments

Apart from the minimally invasive treatments provided by interventional radiology (IR), there are a number of other strategies available for the management of symptomatic varicose veins.

### Conservative management

Graduated compression hosiery is a mainstay of managing venous insufficiency. Specially designed to provide more compression at the bottom of the leg than the top, the poor functioning of the veins is compensated for and the blood is guided in the right direction.

As well as being used on its own for symptomatic relief, graduated compression hosiery is used after surgical and IR procedures to support and aid the recovery process.

People suffering from varicose veins may find that frequent rest as required with elevation of the legs helps ease symptoms, although this is not always a practical solution.



Exercise may help some patients. This is especially true for those that are overweight, as slimming may relieve symptoms and make treatment possible. © gaspr13

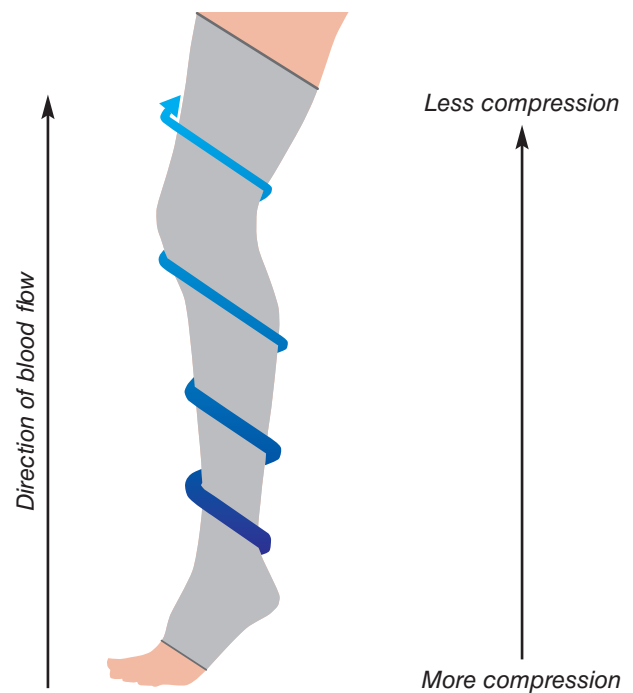
### Vein stripping and ligation

- surgical procedure
- takes one or two hours
- general or spinal anaesthesia required
- full recovery can take up to six weeks

Incisions are made at both ends of the affected part of the vein: in the groin and in the calf or ankle. After cutting the vein at both ends, the surgeon pulls it out of the leg.

The open vein ends remaining in the leg are tied shut and the incisions in the leg are closed. The patient must wear bandages and compression hosiery for a number of weeks after the procedure. Patients can typically return to their normal routine after around two weeks but strenuous activity should be avoided until full recovery.

Although effective, vein stripping is less popular than it once was. Less painful alternatives are now available that have shorter recovery periods and do not require general or spinal anaesthesia.



Specially manufactured support hosiery provides graduated compression; helping the veins to carry blood upwards, towards the heart.

### Ambulatory phlebectomy

This procedure is a less invasive option involving the surgical removal of affected surface veins (phlebectomy).

Many small incisions or punctures are made in the leg, along the path of the symptomatic vein. The affected portions of the vein are then removed through the incisions bit by bit. Only local anaesthesia is usually required.

### Transilluminated powered phlebectomy

This procedure involves phlebectomy and is performed under general or local anaesthesia. A powered resector device and an endoscopic light source are both inserted underneath the skin through incisions made at both ends of the varicosity.

The resector device cuts the problem parts of the vein and removes them by suction. Compression hosiery is worn during the recovery period.

## The diverse role of IR

The previous pages have shown a range of interventional radiology (IR) treatments which are available for the effective management of venous disorders. Interventional radiologists combine imaging expertise and technical skill with catheters and guidewires; allowing treatment of the problem at source.

However, not all venous interventions are in response to a venous disorder. Sometimes the veins are used as access points for diagnostic monitoring (e.g. blood sampling) or systemic therapy (e.g. administration of medication).

### Venous access

When frequent access to the veins is required over a period of time, an intravenous line may be put in place. This facilitates ready access to the venous system; saving time and damage to the vessels by avoiding repeated punctures. Sometimes, due to clinical requirement, access to a large central vein may be necessary. In such cases a central venous line (catheter) is put in place.

### Main reasons for prolonged venous access

- Administration of parenteral nutrition and fluids
- Direct and rapid administration of medication
- Haemodialysis

### IR

We are all familiar with road maps and GPS: tools which help us find our way in new places. Expertise in medical imaging allows interventional radiologists to find their way around the complex pathways of the human body, through the smallest of incisions.

Central venous access may be gained via the surgical route. However, image-guided placement of central venous lines, as performed by IR, has now become standard practice. This has resulted in increased accuracy, decreased procedure time, fewer complications and shorter hospital stays.

Central venous line placement is a commonplace and vital procedure, with a huge number being put in place every year. A large factor in determining which form of line should be used is the duration of access required.

### PICC (peripherally inserted central catheter)

- Duration of access: a few days to three months

Typically inserted into a vein in the arm, this long catheter is navigated through the venous system with the tip reaching the vena cava.

### Tunnelled catheter

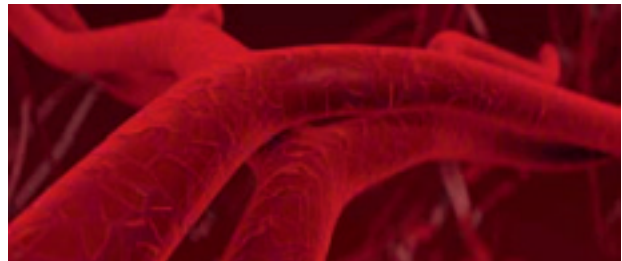
- Duration of access: three to six months

This catheter enters a vein in the upper chest or neck and reaches the vena cava. The catheter exits through the skin (often in the chest) rather than directly from a vein, as with a PICC for example. The exit site is connected to the venous entry point with a “tunnel” under the skin.

### Subcutaneous port

- Duration of access: greater than six months

Subcutaneous vascular access devices can be placed in a surgically created pocket under the skin in the chest. A catheter is threaded through the veins to connect the access device to the vena cava. In this way the device functions as a “port” to central venous access and can be left in the body for as long as required.



Veins and arteries: the complex pathways of the human body. © OPIS

**Image-guided placement of central venous lines has resulted in increased accuracy, decreased procedure time, fewer complications and shorter hospital stays**

### Multidisciplinary expertise

Although line placement is routine, it is not without risk and complications can occur. When introducing catheters and other devices into the body, care must be taken not to cause inadvertent damage. Accuracy of positioning is also vital if the central venous line is to fulfil its role effectively. It is for these reasons that IR is a part of the central venous access team. Using image guidance and excellent device-handling skills, interventional radiologists are able to achieve safe and effective line placement, as well as assessment and repositioning of blocked or dislodged catheters.

The maintenance of central venous access is essential for many patients, and every day IR makes a special contribution to the success of these life-saving interventions.

# Varicose Vein Treatment

## The IR way

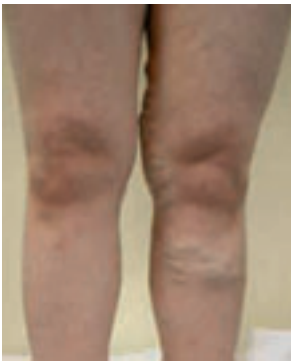### The Patient

Ms. Feraye Kılıç, a patient of Prof. Levent Oguzkurt, explains how undergoing interventional radiology (IR) treatment for varicose veins made a real difference to her life:

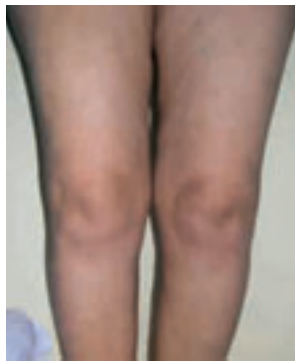*“After my second pregnancy, unsightly varicose veins appeared on my left leg and got larger and larger over the last three years. The appearance was only one part of the problem. In my right leg, there was mild pain and heaviness. My left leg became heavier with walking and I had pain and got easily tired after walking for 10-15 minutes. I also started to experience cramps in my calf muscles which usually occurred during the night. At times, the numbness and pain extended to my left foot.*

*“I wanted to have my legs treated. The vascular surgeon that I visited recommended surgical removal of the varicose veins and the vein that caused it, but I had doubts over surgery as I had heard that the recurrence of varicose veins was high.*

**I have been relieved of all my pains and can walk freely**



The patient before treatment. Varicose veins can be seen on the left leg.



The patient after treatment with endovenous laser ablation.



*“I heard about the laser procedure and was examined. My doctor, an interventional radiologist, performed the ultrasound examination himself and told me that I had insufficiency of the left great saphenous vein and both small saphenous veins. He suggested laser ablation of the incompetent saphenous veins and sclerotherapy for varicose veins.*

*“The procedure was done using intravenous pain medication with a nerve blockade and lasted about an hour. It was very comfortable and I did not feel any pain or discomfort during the procedure. I could walk about 30 minutes after the operation and went about my usual daily routine. The area of laser ablation caused some mild pain for the next week but I was comfortable after using some pain medication.*

*“One year after the operation, I have been relieved of all my pains and heaviness and I can walk freely and I feel ‘light’ again. Before the treatment, I could not keep up with my friends while walking together – now they can’t keep up with me! I work in the fields and in the past I could only manage to walk around less than an acre before getting tired and needing to stop and rest; now I can manage five acres at a time. My legs look completely normal which also makes me feel better.*

*“My life really changed after the laser procedure. Now I am pain-free and I feel happier and much more energetic!”*



## The IR

**Prof. Levent Oguzkurt spoke to IQ about the particular strengths of interventional radiologists, which enable them to provide excellent treatment for symptomatic varicose veins:**

*“Our hospital is one of the biggest centres in Turkey for laser ablation of varicose veins. Since 2007, when we started providing IR treatments for this condition, we have performed more than 1,500 thermal ablation procedures. This popular procedure is carried out via the hospital’s outpatient clinic for varicose veins.*

*“The most important advantage of IR techniques in this field is the combination of expert ultrasonography and percutaneous minimally invasive therapy methods. The two of these together are necessary for really excellent treatment of varicose veins. IR is ideally suited to the treatment of varicose veins since both of these diagnostic and treatment steps are well within the skills portfolio of the interventional radiologist.*

*“To begin with, excellence in ultrasonography underpins a familiarity with variable anatomy and allows correct diagnosis of the problem. Then, ultrasound technique is vital for the orientation of the treatment (puncture and tumescent anaesthesia guidance) and for examination and evaluation of the patient at follow-up.*

*“IR has become a strong presence in the field of varicose vein treatments and this is set to continue. Our use of modern imaging techniques allows an excellent depiction of anatomy, so we can see the pathophysiology in more detail and understand its association with the symptomatic complaints, which can impact so strongly upon a patient’s quality of life.*

*“As doctors with experience and know-how in both ultrasonography and minimally invasive therapies, interventional radiologists are well equipped for the effective treatment of varicose veins.”*

*With very special thanks to Feraye Kılıç*

*A.M.*



**Prof. Levent Oguzkurt**, Interventional Radiologist, Radiology Department of Başkent University Faculty of Medicine and Chief of Interventional Radiology Section, Adana Medical Center, Adana, Turkey



**Diagnostic and treatment steps are well within the skills portfolio of the interventional radiologist**

# Voting With Their Wallets

## The rising demand for non-surgical varicose vein treatments

Minimally invasive treatments for varicose veins are offering patients more choice than ever, and even where they are not offered by public health insurers, patients are voting with their wallets and seeking out private treatment.

Dr. Kieran McBride runs the Scottish Vein Centre, a private clinic in Edinburgh that offers varicose vein sufferers the gentle options they are looking for. He tells us why the procedures are so popular, and why, having trained as both a surgeon and an interventional radiologist, he favours the minimally invasive approach.

### The public purse

The term 'endovenous ablation' sounds complicated, but it's basically burning the vein from the inside. Data has been building up over the last 10 years, and there's a lot of indisputable evidence now. Nonetheless, there is a reluctance in Europe to provide it on the public purse.

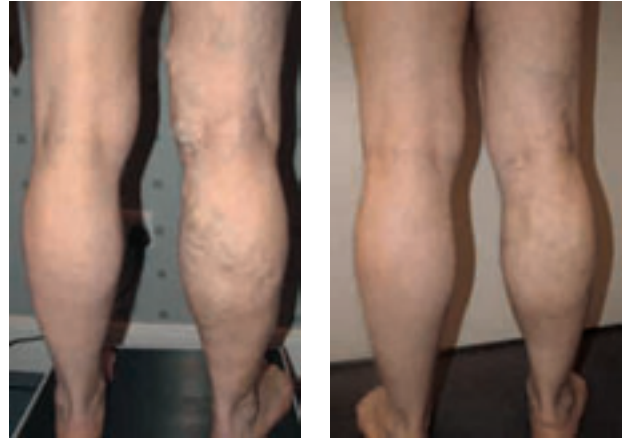
### The US experience

In the US, ablation has now become the accepted standard for patients, surgeons and insurance companies. Endovenous laser is the proven superior treatment – there's plenty of data to support it.

In 2005, the American private insurance companies decided to pay for it, as it was the cheaper option. So literally overnight, surgeons were realising that a less invasive, non-surgical outpatient procedure meant better refunds. Now, only about 10-15% of veins are being operated on in America. It's the other way around in the UK.

### The public mood

In Europe, people who are experiencing heavy, uncomfortable legs, or who are unhappy with the appearance of



Following retirement, a butcher who had suffered from varicose veins for 30 years underwent laser ablation with a foam sclerotherapy follow-up.

their legs are often reluctant to opt for surgery. But their veins have a huge impact on their quality of life, and when they know interventional radiology (IR) is an option, many are happy to pay to have their knarled and painful veins rectified.

### The limitations of surgery

Surgeons generally cut at the groin and tie off the incompetent vein, then pull it out: but stripping can be very inefficient. Little bits of vein come out, but not the whole vein. Even if the procedure is completely successful, patients are still left with scars.

With certain veins, such as the short saphenous (the veins at the back of the knee), there's a high recurrence rate and a high complication rate with surgery and these veins especially do better with the less invasive methods.

Another drawback to surgery is neovascularisation: 25 of my patients have had a recurrence from surgery called a varix. That's when a large number of small veins regrow from the cut vein, and they're difficult to deal with surgically. So I introduce a catheter, followed by a fibre optic. Before I turn on the laser, I inject a foam sclerosant, which fills all of the varices that are all bunched together. I've had really good results, even at 4-year follow-up.

Neovascularisation is avoided with laser or radio frequency where the vein remains closed. So you actually inhibit new growth, you're preventing that recurrence.

Endovenous laser is the proven superior treatment – there's plenty of data to support it



**Patient choice**

Ultimately, it's about patient choice. The big question that I put to surgical colleagues is "how do you get fully informed consent without giving patients all the options?" A lot of patients don't know about the new procedures, but neither do all general practitioners (GPs), which is really unfortunate for a lot of people.

**Missed diagnoses**

In most cases, varicose veins cause discomfort and embarrassment, but patients can also end up with bad ulcers, real problems. They may already have hidden deep vein thromboses (DVT) or other underlying problems. A lot of GPs don't examine legs: they don't know how. So there's a bit of education needed in primary care.

Many of our patients find out about IR from newspapers or from websites; they type 'varicose veins' into Google, and come across websites like mine. When I see a new patient, I inform their doctor, and I make efforts to spread the word.

**The Scottish Vein Centre**

I've based my Scottish Vein Centre on the American walk-in-off-the-street set-up – I work out of private consulting rooms. We have adapted our consulting room to be able to perform sterile procedures in a relatively relaxed and informal environment. The patients are kept very comfortable and have an attendant with them throughout the procedure, while pleasant background music is playing.

Every new patient undergoes an assessment, a consultation and a fully detailed ultrasound examination. We give them maximum information, and send them away to think about it. I always tell them to call the following day or the following week. It's important that they've thoroughly considered their options.

We do our procedures on a Saturday on an outpatient basis, and the patient is usually back at work by Tuesday. It's done under local anaesthesia and is finished within an hour. We put the patient in some compression bandages and compression stockings, and they can walk out of the department and to the shops, or whatever they feel like.

We've never received a complaint and have had a full 100% technical success rate



**Satisfied clients**

We've always had very satisfied patients. My clinic has been running for six years now, and we've never received a complaint and have had a full 100% technical success rate. An important part of that is making sure that patients have realistic expectations – we do emphasise that we're not going to give them Sofia Loren's legs! But they will be rid of their varicose veins.

However it's not just about cosmetics: quite a number of patients are actually quite symptomatic – probably about 70-75% will have some degree of symptoms and although serious outcomes are rare, varicose veins are very distressing for many people – so much so that they are willing to pay privately for a solution to their problems.

I'm delighted to be able to provide this service – it's wonderful to be able to make a difference to people's everyday lives.

C.M.

[www.scottishveincentre.co.uk](http://www.scottishveincentre.co.uk)



# Worldview



**Dr. Sanjoy Kundu**, Medical Director of the Vein Institute of Toronto and Active Staff at the Scarborough Hospital, Toronto/Canada

*“Image-guided treatments for **varicose veins**, including endothermal ablation and ultrasound-guided sclerotherapy, have revolutionised the treatment of superficial venous insufficiency. These treatments are characterised by markedly improved outcomes, decreased complications and reduced recovery time.*

*“The unique skill set of IRs means that they are optimally positioned to advance treatments in this arena. The future is very bright: since our practice began in 2003 it has continued to grow by 10% each year.”*

### In the clinic

Mr. Sheldon Strong, a patient of Dr. Kundu who underwent endovenous laser ablation, shares his story:

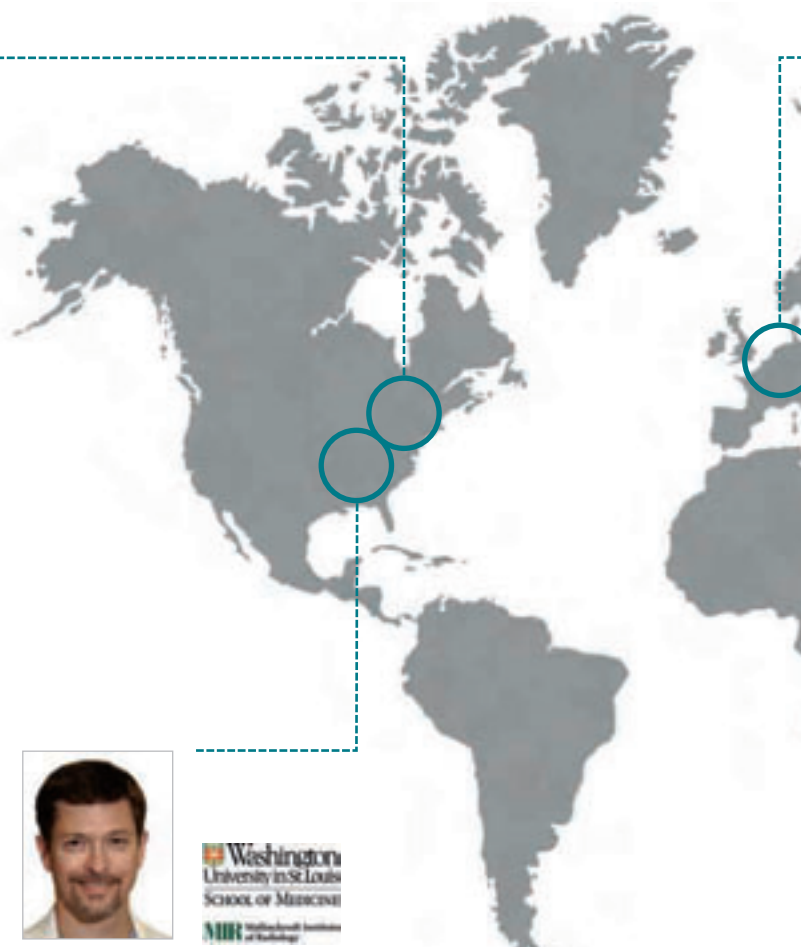
*“For most of my adult life I have been seriously compromised by a large varicosity in my right leg. While only mildly uncomfortable most mornings, within two hours of being on my feet, my right leg, and particularly my right foot would begin to pound with a pain that elevation and Tylenol would only begin to ease.*

*“Elevation was rarely an option during the day; hence the pain was often close to unbearable by the evening. In addition to my concerns with the resulting reduction in activity, as a diabetic, I feared the formation of leg ulcers. “I had considered surgery, but had not pursued it as a treatment option. Although desperate for a ‘cure’, the length of the recovery period, the unpredictable outcome and the risk of infection and other complications made surgery a risk I was not prepared to take.*

*“The procedure I underwent, laser ablation therapy, was painless; and amazingly, I walked out of the office after one hour, with no restriction in activity, wearing a full leg support hose for six weeks afterwards. Today, I can tell you that my life has changed. I can be on my feet all day long without pain of any kind.”*

Excellent clinical care

*“From the first consultation I knew I was in the hands of a capable professional. Dr. Kundu listened patiently, answered my questions, educated me, and inspired great confidence. The Vein Institute sets an amazing example of efficiency, thoroughness, sincere caring and support.”*



**Dr. Michael Darcy**, IR, Chief of Interventional Radiology, Mallinckrodt Institute of Radiology, Washington University in St. Louis/USA

*“Barnes-Jewish Hospital is the primary hospital for the Washington University in St. Louis Medical School. Our IR section has provided the advantages of minimally invasive **varicose vein** treatments since 2004.*

*“With our imaging background, we IRs are more comfortable with ultrasound guidance of needles, ablation devices, and tumescent anaesthesia delivery than some other specialties. Our ability to expertly use steerable wires and catheters allow us to easily overcome problems like severe spasm, vessel tortuosity, or to get past very large varicosities that the wire might preferentially go into.*

*“New techniques for ablating major truncal veins are on the horizon and these have potential to make ablation procedures quicker, easier, and safer.”*

### In the clinic

*“A 72-year-old woman had leg swelling, pain, and cellulitis (soft tissue infection) resulting from venous stasis (poor drainage of blood from the leg). Ultrasound showed a very large great saphenous vein with abnormal backward blood flow (reflux). Laser ablation of this vein was done as an outpatient procedure with only local anaesthesia. When seen one month later, the swelling in the patient’s leg had significantly improved, her cellulitis had resolved and she was very happy that her leg pain was gone.”*



**Dr. Luc Stockx, IR, Ziekenhuis Oost Limburg, Genk/Belgium**

*“The IR treatment of **DVT** at our large community hospital is the result of a close relationship between the department of vascular surgery and interventional radiology. Treatment can only be successful if such close co-operation is in place and if all patients presenting with DVT follow the same pathway.*

*“There are many advantages of catheter-directed thrombolysis:*

- Early relief of symptoms by restoring patency and flow
- Preservation of venous valves and their function: plays a major role in the prevention of post-thrombotic syndrome
- Detection of underlying lesions and the possibility of treatment within the same session

*“New mechanical thrombectomy devices and new drugs which are more active and selective will shorten the treatment time while making it safer.”*

#### **In the clinic**

*“A 36-year-old woman came to the emergency department with an extremely swollen and painful left leg. Using ultrasound, we found a deep venous thrombosis of the left femoral vein, extending into the iliac vein. A catheter was introduced via the popliteal vein behind the knee and the thrombolytic drug urokinase was infused.*

*“When blood flow through the vein was restored, we found that the DVT had come about due to Cockett’s syndrome. Here, the common iliac artery compresses the underlying common iliac vein, causing it to narrow. This narrowing was successfully treated with the introduction of a stent. Three days later, the patient could leave the hospital without any complaints and with an almost normal sized leg.”*

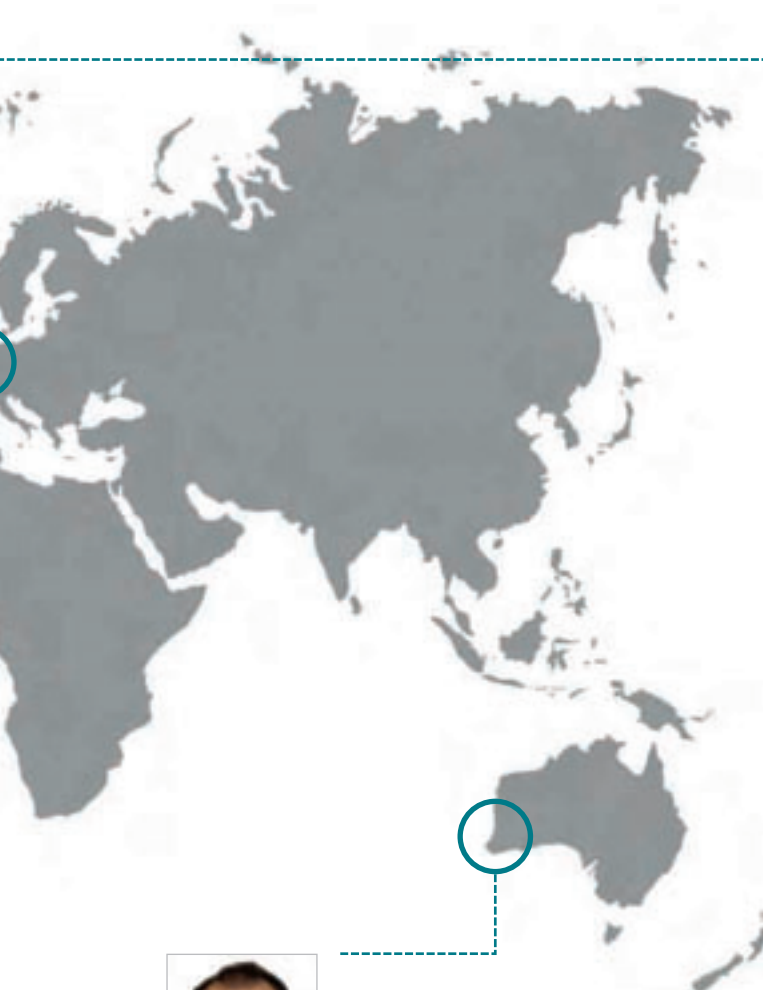*“The advantages mean there is no doubt that these procedures will replace traditional stripping surgery. Awareness of this procedure is growing and IRs continue to inform other doctors and specialists, as well as patients, about the benefits of the procedure.”*

#### **In the clinic**

Ms. K. Rowland, a patient who underwent treatment in August 2011 shares her experience:

*“The procedure itself, in the sense of it being quite non-invasive, was very convenient. It is not like going into hospital, having hospital costs and being put under a general anaesthetic then having your veins stripped.*

*“The varicose veins treatment was very successful, the veins have completely gone. I had my veins done many years ago, which left many surrounding spider veins. This treatment, however, was complete. The spider veins treatment was amazing because my legs were covered, particularly with dark veins behind my knees and they have now completely gone, which is fantastic. I would recommend it to others, especially people that have quite noticeable veins.”*



**Dr. Sanjay Nadkarni, IR, Director of Endovascular WA, Claremont/Australia**

*“Our private clinic is dedicated to the minimally invasive treatment of **varicose veins** and peripheral artery disease. All vein cases are treated as outpatients as a walk in/walk out procedure.*

*“Since 2005 we have performed over 2,000 procedures for varicose veins. The procedures offered are endovenous laser ablation and radiofrequency ablation; ambulatory microphlebectomy; ultrasound-guided foam sclerotherapy and microsclerotherapy.*

*“These treatments have several strengths:*

- Less invasive than surgery (vein stripping)
- No need for hospital admission or general anaesthetic
- Walk in/out with return to work immediately or the following day
- Lower chances of major complications, especially nerve injury and infection
- Potential for lower recurrences
- No radiation as the procedures can all be done under ultrasound guidance



# Turning the tide of venous insufficiency

## How IR is pioneering the development of prosthetic valves

Innovation and constant technical development are some of the hallmarks of interventional radiology (IR). One area in which interventional radiologists are applying their ingenuity is in the search for a new solution to chronic venous insufficiency (CVI).

Thanks to the great contribution of Prof. Elias Brountzos and Prof. Dusan Pavčnik, two interventional radiologists involved in this field of research, IQ explains how prosthetic venous valves could become an effective new treatment option.

### A widespread disease

Many people worldwide suffer from chronic insufficiency of the veins in the legs. Weak and leaky valves in the veins result in the pooling of blood in the legs and raised blood pressure in the local venous system (for further details, see Venous Interventions, page 5).

Venous insufficiency can lead to many symptomatic problems, the most familiar of which being visible varicose veins: a sign of insufficiency in the superficial veins close to the skin.

#### Symptoms of chronic venous insufficiency:

- Visible red or “broken” vessels
- Visible varicose veins
- Disabling pain
- Skin changes including discolouration
- Oedema (swelling due to fluid retention)
- Sclerosis (hardening of the tissues)
- Skin ulceration

A range of treatments are available for superficial varicose veins, including highly effective and minimally invasive options provided by IR.

#### Treatments for superficial venous insufficiency:

- Foam sclerotherapy
- Radiofrequency ablation
- Laser ablation
- Compression hosiery
- Surgical stripping and ligation

### More than skin deep

Primary CVI

- uncertain causation
- thought to be congenital

Secondary CVI

- post-thrombotic
- deep vein thrombosis damages or destroys valves of the *deep veins*

When the deep veins are affected by CVI, the treatment options are much more limited. Surgical treatments exist such as valve repair, femoral vein transposition or venous segment transplantation. However, the majority of patients with secondary valve insufficiency are not candidates for these procedures due to obstructions or residual thrombus throughout the vein.

The few remaining treatment options for these patients include the use of compression stockings and local skin treatment. This is often inadequate and non-healing ulcers can easily develop.

### Early involvement of IR prevents later complications


Interventional radiology has developed techniques for the prevention of secondary venous insufficiency after a DVT. However, thrombolysis and recanalisation of the acute deep venous thrombosis are still unfortunately only offered to a minority of patients. The majority of patients are managed conservatively with anticoagulation only and are at risk of going on to develop secondary CVI of the deep veins. An effective therapy is needed for these patients and, once again, IR might be able to offer the solution.

### Treating the source of the problem

In the field of cardiac surgery, the implantation of specially designed artificial valves is already routine. Furthermore, prosthetic valves can now be put in place with minimally invasive catheter procedures for selected patients, who are unsuitable for open surgery. If it is possible to replace faulty valves in the aorta, could it be done in the veins?

In 1981, IR pioneer Charles Dotter proposed the minimally invasive implantation of an artificial venous valve. This was suggested as a solution for patients with chronic deep venous insufficiency for whom surgical treatment had failed.

Since then, much research has gone into the development of catheter-based valves that are suitable for percutaneous placement into insufficient veins.



*Prof. Elias Brountzos,  
Department of Radiology,  
University of Athens,  
Greece*



*Prof. Dusan Pavčnik,  
Dotter Interventional  
Institute, Portland,  
OR, USA*

## If it is possible to replace faulty valves in the aorta, could it be done in the veins?

### Designing a solution

Many designs for prosthetic venous valves have been conceived but despite significant progress in the area there are still many challenges to be overcome before they are seen in the clinic.

One of the major difficulties encountered with all vascular prosthetics is neointimal hyperplasia: a thickening and growth of the blood vessel's lining after a device is put in position. This is a natural response when a foreign body comes into contact with the blood vessel but can lead to a narrowing (stenosis) of the vessel, which restricts blood flow and limits the effectiveness of the treatment.

For useful clinical application, prosthetic venous valves must be compatible with the body, remain in position and keep functioning in the long term.

#### The ideal prosthetic venous valve for treating deep venous insufficiency:

- Good long-term function
- Minimally invasive placement by catheter
- Good biocompatibility
- Low risk of thrombus formation
- No need for anticoagulation medication

### IR at the forefront

One research group that is making great strides in the development of artificial venous valves is that headed by Prof. Dusan Pavčnik, at the Dotter Interventional Institute, Oregon, USA. Their concept is to use the biosynthetic valve material, porcine small intestinal submucosa (SIS), which is attached to a metallic square stent frame.

Following promising experimental studies, trials with symptomatic patients have shown good results in the short term. Patients' symptoms improved and, in some cases, large venous ulcers completely healed. Spurred

on by these positive clinical results, the next step is to enhance the long-term functioning of the valve, preventing neointimal hyperplasia so that the leaflets remain in good working condition for longer.

Other than finding a new biomaterial to use instead of SIS, valve functionality could be enhanced by finding a method for SIS leaflets to be covered with vein wall cells. In this way, neointimal hyperplasia might be prevented. The artificial valve might then be allowed to work as if it were a natural part of the vein.

Recognising the great potential of this idea, the Dotter Institute has recently been awarded an NIH R01 grant from the US Department of Health, to investigate this promising technology.

### A small device with huge impact

The clinical availability of a bioprosthetic venous valve would revolutionise the treatment of chronic deep venous insufficiency, a condition for which there is currently no satisfactory standard treatment.

As well as reducing the costs currently spent on long-term care and disease management, bioprosthetic venous valves could also greatly improve the health and quality of life of countless patients around the world.

A.M.

## Trials with symptomatic patients have shown good results in the short term

# Economy Class Syndrome

## An Economic Nightmare

**Deep vein thrombosis (DVT), often referred to as Economy Class Syndrome, is a well-known medical complaint much discussed in lifestyle magazines. Unsurprisingly – in a world where long-haul flights and sedentary lifestyles are so prevalent, we are more at risk than ever before.**

### What is DVT?

DVT is the formation of a blood clot within the veins that lie deep within our muscle tissue. This is most common in the legs, but can also occur in other body parts, such as the arms (roughly 10% of cases).

When circulation slows (due to illness, injury or inactivity), blood can pool within the vein and begin to clot. Once a clot forms, it can cause the limb to swell or become painful. Skin discolouration is usual, as is abnormal warmth, and the surface veins may become more visible. Mobility can be affected by the uncomfortable symptoms.

### Pulmonary embolism

More worryingly, if the clot breaks free, it can travel to the lungs in the blood supply (pulmonary embolism). With the lungs' oxygen supply wholly or partially blocked by the clot, heart failure can result. Thromboembolisms such as these are the third biggest cause of cardiovascular mortality after stroke and heart attack. Early treatment of patients with DVT reduces the risk of pulmonary embolism to less than 1%.

### Who is at risk?

The following can all play a contributory role in causing DVT:

- Family/personal history of DVT
- Hormone therapy or oral contraceptives
- Pregnancy or having undergone labour recently
- Obesity
- Immobility (such as bed rest, or long-haul flights)
- Recent surgery
- Previous or current cancer
- Limb trauma
- Coagulation abnormalities
- Aged above 40
- Smoking

### Treatments

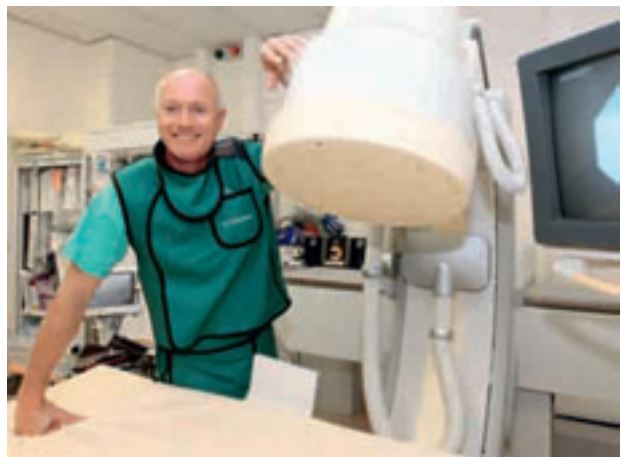- **Anticoagulants:** blood thinning substances. These do not dissolve the clot, but prevent further clots forming.
- **Compression stockings:** the added pressure reduces likelihood of blood pooling and clotting.

- **Catheter-directed thrombolysis:** local catheter delivery of clot-dissolving drugs. As these drugs carry a risk of dangerous bleeding, they are only used for more serious cases.
- **Mechanical thrombectomy:** tiny pincers or vacuums are sent in on a catheter to remove the clot.
- **IVC filtration:** small umbrella-shaped filters are placed within the vena cava to prevent any clots that break loose from reaching the lung – good for patients for whom anticoagulants aren't suitable.
- **Angioplasty/stenting:** a catheter-delivered balloon and/or stent can be used to reopen the blocked section of vein.

### Post-thrombotic syndrome

A common<sup>1</sup> after-effect of DVT is post-thrombotic syndrome. If the original clot is left in place, it can continue to obstruct the vessel it is lodged in. This increases the pressure within the vein, and symptoms such as aching, itching and swelling may occur. These symptoms can be very debilitating – furthermore, they can progress to painful and difficult-to-treat ulcers in 5-10% of DVT patients<sup>2</sup>. Symptoms can occur up to two years following DVT. There is growing evidence that in selected cases of DVT, interventional radiology (IR) clot removal can significantly reduce the incidence of PTS.

## Ask the Expert



Dr. Gerard O'Sullivan is an interventional radiologist at University College Hospital Galway, Ireland. He explains the importance of IR in combating DVT.



**Why is it important to treat DVT – what can be the consequences of not doing so?**

*“DVT can have serious consequences: venous thromboembolism (VTE) is the third biggest cause of cardiovascular mortality after stroke and heart attack. Additionally, post-thrombotic syndrome affects a large proportion of patients post-DVT and is disastrous in terms of morbidity. Multiple long-term studies have shown huge medical costs and marked loss of ability to perform everyday activities such as standing or working.”*

**How common is DVT?**

*“Exact numbers are hard to come by, but there are about 200,000 new DVTs in the USA each year: within Europe, with an approximately comparable population, the numbers will probably be similar. Unlike arterial disease, VTE affects both young and old with devastating consequences.”*

**What are the IR treatment options, and how do they compare with alternative medical and surgical options?**

*“Traditional treatments are anticoagulation and rest, but these are based on trials from the late 1950s. Traditional treatments fail to prevent PTS (leg swelling, discolouration, heaviness, cramping, which may progress to ulceration, etc.) in more than 70% of proximal (ilio-femoral) DVTs.*

*“More aggressive interventional radiology-based therapies include catheter-directed thrombolysis, thrombectomy, IVC filtration, angioplasty and stenting. Although there is not as yet Level 1 evidence for these therapies, there is plenty of supportive evidence emerging. In essence, the risk of PTS is at least halved by IR-based therapy.”*

**What sorts of outcomes do you get from thrombectomy/local thrombolysis?**

*“My patients recover within hours from these therapies: their leg swelling begins to improve within 4-6 hours, and they are fully mobile by the following day. Most are walking several miles by the end of the first week. I have treated several triathletes who are competing again, having been literally bedbound prior to therapy. Patient feedback has been extremely supportive – as has that of the referring clinicians. Indeed, the most supportive referrers have been my oncological and palliative care colleagues, who see patients’ leg swelling decrease rapidly, enabling them to be discharged early.”*

**(IRs’) thrombectomy and local thrombolysis skills have proved invaluable in the more severe cases**

**The Colleague’s Perspective**

Dr. Maccon Keane is a Medical Oncologist at University Hospital, Galway. He is a keen supporter of IR, and works closely with Gerard O’Sullivan and his colleagues.

*“Our Oncology Department has been working closely with the IR Department since 2003. Oncology patients, due to a variety of factors, such as altered blood chemistry and increased bed rest, are quite prone to developing blood clots. They’re probably the single biggest risk group, actually; there’s a very high frequency of both of DVT and pulmonary embolism.*

*“Among oncology in-patients, there is a 5-10% incidence of DVT. Not all of these will require IR intervention, but all will require some form of treatment, and the IR therapies are a great option to have available. Their thrombectomy and local thrombolysis skills have proved invaluable in the more severe cases.*

*“Our oncology department (and indeed, every oncology department I’ve ever worked in) would be one of the top users of IR services within the hospital. We require their assistance with thrombotic events, biopsies, stent placement, and a variety of other issues that arise routinely in medical oncology.”*

C.M.

1 PTS occurs in 20-40% of patients after an episode of lower extremity DVT according to the Venous Disease Coalition; and in 60-70% according to the SIR.  
2 Venous Disease Coalition

# Venous Disorders

## Widespread and costly

The high cost of venous disorders is guaranteed by the sheer number of people affected. Alongside the expenses of acute treatment and long-term care, the wider economy must absorb associated costs, such as the high number of missed work days.

### A European example: the situation in Germany

#### Chronic venous disease

A German study into the prevalence of venous disorders found every 6<sup>th</sup> man and every 5<sup>th</sup> woman to have chronic venous insufficiency.\*

Over 90% of people aged 18-79 were affected to some degree by a chronic venous disorder (see figure opposite).

The incidence of venous disorders was generally seen to increase with age (see chart below). Given the ageing population, this has serious implications for healthcare payers.

#### Acute venous disease

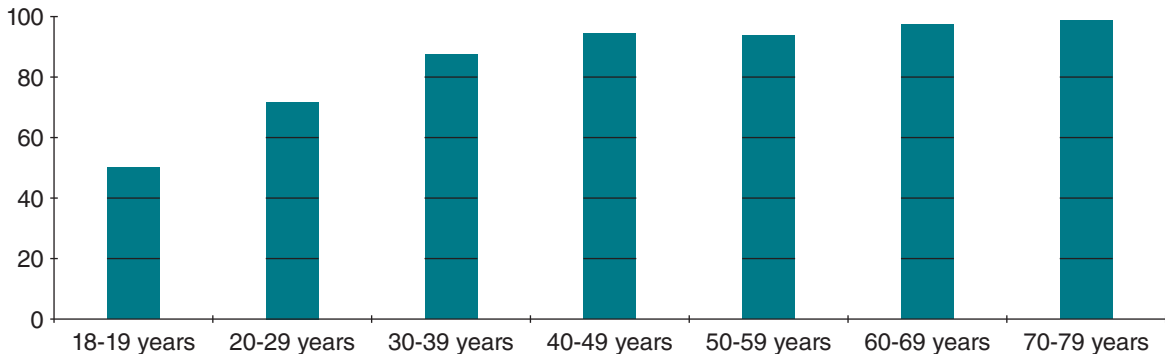
Surveys indicate that up to around 5% of the population have experienced deep vein thrombosis (DVT) in the past.

For every 1,000 people in the population, one or two new cases of DVT arise each year. As well as acute intervention being needed, chronic problems such as post-thrombotic syndrome can arise, requiring further care.

#### Costs

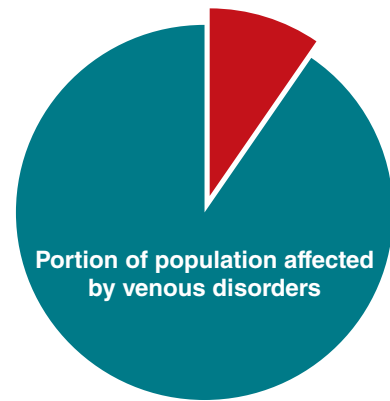
Initial treatment costs are only the beginning. Long-term nursing care and management of complications is often necessary. In 2006, the healthcare costs just for varicose veins of the legs amounted to € 808 million in Germany.

Percentage of age group affected



Prevalence of venous disorders (C1-C6) increases with age

\* Bonn Vein Study: conducted by the German Society of Phlebology, in co-operation with the German Ministry of Health. Phlebologie 2003; 32: 1-14



Prevalence of chronic venous disorders

CEAP Classification of venous disorders	Affected population
<b>C0:</b> No detectable venous disorder	9.6 %
<b>C1:</b> Telangectasia or reticular veins only	59.0 %
<b>C2:</b> Varicose veins (diameter ≥3mm)	14.3 %
<b>C3:</b> Oedema due to venous insufficiency	13.4 %
<b>C4:</b> Skin changes due to venous insufficiency	2.9 %
<b>C5:</b> Healed venous ulcer	0.6 %
<b>C6:</b> Open venous ulcer	0.1 %

AOK, one of Germany's biggest health insurers covering around 24 million people, reported in 2006 that for every 1,000 members more than 200 work days were lost as a result of venous thrombosis and varicose veins.

Although there is still room for improvement, the direct costs of venous disease have started to decrease in recent years. This trend corresponds with a rise in outpatient procedures being performed, avoiding costly hospitalisation.

**The wider availability of effective minimally invasive options is therefore not only in the interest of patients, but also beneficial for healthcare payers.**

A.M.

Information on this page adapted from Gesundheitsberichterstattung des Bundes, Heft 44: Venenerkrankungen der Beine; Robert Koch Institute, 2009.



# Venous Interventions Trials and Registries

**Trial:** a study carried out with the purpose of testing a new medical treatment on a defined group of people. The results are compared with a group that are treated using another method and/or a control group.

**Registry:** a (retrospective) collection of data about a certain treatment or illness. Using the compiled data, conclusions can be drawn about effectiveness of a particular treatment method.

## Early Outcome of Mechanochemical Endovenous Ablation (ClariVein-2)

**Contact**

Dr. Michel M.J. Reijnen, Rijnstate Hospital, NL

**Date opened**

November 2011

**Status**

Recruiting

**Description**

Mechanochemical endovenous ablation is a new tumescentless technique that combines a rotating wire with the infusion of a liquid sclerosant. The study aims to evaluate the short and long term outcome of mechanochemical endovenous ablation.

**ClinicalTrials.gov Identifier:** NCT01459263

## Acute Venous Thrombosis: Thrombus Removal with Adjunctive Catheter-Directed Thrombolysis (ATTRACT)

**Contact**

Dr. Suresh Vedantham, Washington University School of Medicine, US

**Date opened**

November 2009

**Status**

Recruiting

**Description**

The purpose of this study is to determine if the use of adjunctive Pharmacomechanical Catheter Directed Thrombolysis can prevent the post-thrombotic syndrome (PTS) in patients with symptomatic proximal deep vein thrombosis (DVT).

**ClinicalTrials.gov Identifier:** NCT00790335

*Please note, this does not constitute an exhaustive overview of trials and registries. If you are aware of a trial or registry which may be of interest to our readers, please feel free to contact us at [info@intervention-iq.org](mailto:info@intervention-iq.org).*



- [www.intervention-iq.org](http://www.intervention-iq.org)
- [www.clinicaltrials.gov](http://www.clinicaltrials.gov)
- [www.cirse.org](http://www.cirse.org)
- [www.controlled-trials.com](http://www.controlled-trials.com)
- [www.who.int/trialsearch](http://www.who.int/trialsearch)
- [clinicaltrials.mayo.edu](http://clinicaltrials.mayo.edu)

## Pulmonary Embolism Response to Fragmentation, Embolectomy & Catheter Thrombolysis: PERFECT

**Contact**

Mr. William T. Kuo, Stanford University School of Medicine, US

**Date opened**

January 2011

**Status**

Not yet recruiting

**Description**

A prospective observational study to evaluate the safety and effectiveness of catheter-directed therapy (CDT) including percutaneous mechanical thrombectomy (PMT) for treatment of acute pulmonary embolism (PE).

**ClinicalTrials.gov Identifier:** NCT01459263

## Ultrasound-enhanced Thrombolysis versus Standard Catheter Directed Thrombolysis for Ilio-femoral Deep Vein Thrombosis

**Contact**

Dr. Nils Kucher, University Hospital and University of Bern, CH

**Date opened**

November 2011

**Status**

Recruiting

**Description**

The hypothesis for this study is that ultrasound-enhanced thrombolysis reaches a higher degree of thrombolysis than standard catheter-directed thrombolysis (CDT) in patients with symptomatic ilio-femoral Deep Vein Thrombosis (DVT).

**ClinicalTrials.gov Identifier:** NCT01482273

## Ultrasound Accelerated Thrombolysis of Pulmonary Embolism (ULTIMA)

**Contact**

Dr. Nils Kucher, University Hospital and University of Bern, CH

**Date opened**

July 2010

**Status**

Recruiting

**Description**

The ULTIMA study is intended to prove that patients with pulmonary embolism and a right ventricular end diastolic diameter to left ventricular end diastolic diameter ratio  $\geq 1$  (RV/LV ratio) will benefit from treatment with ultrasound accelerated thrombolysis (rt-PA) as compared to anticoagulation.

**ClinicalTrials.gov Identifier:** NCT01166997

*IQ takes no responsibility for the content of the individual trials and registries; please refer to their source for further information.*

# Weighing Up the Benefits of IR

## An economist's perspective

In an ideal world, patients would have unlimited access to all the treatments they might need. In reality, however, healthcare decision makers face the difficult task of balancing need with availability. With limited resources, cost effectiveness is central to any decision.

Lieven Annemans, Professor of Health Economics at Ghent University and Brussels University (VUB) and author of "Health economics for non-economists" talks to IQ about how interventional radiology (IR) rates, and what interventional radiologists and hospital directors should bear in mind.

### Why do you think it's important for doctors to understand health economics?

*For too long, doctors and nurses have only been considering the health consequences when treating a patient. That's normal: when you have a patient in front of you, you want to make them better. But we have to be realistic and accept that there are budgetary limits. On the other hand, there are also managers of hospitals or regions that focus too much on cost and on budgets, and that's not good either.*

*The objective of healthcare is to gain health in the population – but you have to gain this by respecting the cost-effectiveness of what you are doing.*

### What can be done to end this stand-off?

*I see the role of the health economist as finding a compromise. What exists now is a kind of deaf man's discussion – neither side will listen to the other. People tend to stay in their comfort zone, and so doctors may try to avoid discussing economics, but if they can understand some of the principles and basic calculations used, they will better be able to enter a constructive debate.*

*Understanding the ratio between costs and effects and recognising which therapies should be prioritised and preferred is very helpful to this discussion. If doctors can feel comfortable reading and using this language of economics, they will find themselves better able to negotiate.*

### How cost-effective is IR?

**The objective of healthcare is to gain health in the population – but you have to gain this by respecting the cost-effectiveness of what you are doing**

*I have been involved in evaluating the management of critical limb ischaemia (CLI), and while the technologies are changing all the time, what has been studied so far looks good. Peripheral vascular interventions are cost-effective compared to doing nothing and compared to surgery. So in that field it is quite clear that overall, the ratio between its costs and its effects is very favourable.*

*There are many interlinking factors to consider when coming to a conclusion like this. Even when a therapy might seem expensive, you need to weigh that cost against outcome and impact: if the treatment is beneficial to the health of the patient, that is not only good in itself, it could actually save money in the long-term.*

*If an expensive intervention such as coil embolisation leads to improved disability levels in a stroke patient, then you have saved yourself the costs of the chronic intensive care that would otherwise be needed for the remainder of their life, which could run to tens of thousands of euros. But you have to demonstrate this first, of course – good, solid data is crucial.*

### Randomised Controlled Trials (RCT) are both expensive and require large patient populations – how do you suggest interventional radiologists find convincing data?

*The first thing to do, in my view, is to observe patients treated with a new technique. Develop a case series*



and compare your findings with historical controls. OK, it's not randomised and you have to correct for possible differences in patient characteristics and so on, but at least it gives you a good idea of the potential benefits of the new technique. Smart payers know that an RCT is not always possible and, therefore, they should be open to your evidence.

**Where does one start – how do you get approval for those first patients?**

One tried and tested method is to develop clinical guidelines that take cost-effectiveness into consideration. That's not an easy task, but your message would be much stronger if you say, "this technique is effective and first data shows potential cost-effectiveness."

If a technology is still in development, but has good preliminary evidence supporting it, your hospital manager, regional decision maker or health insurer can try to reach a performance-based agreement with the company, saying, "your evidence base is not yet perfect, but we will cover a part of the costs and run a case series, allowing you to broaden your data."

If the company's claims were found to be true, or if the technology has a greater application than predicted, the agreement can be revised. Interventional radiologists can play a key role in advising and supporting their management in such a venture, which is beneficial for the hospital – it allows you to offer your patients cutting-edge technology at a preferential price.

**Peripheral vascular interventions are cost-effective compared to doing nothing and compared to surgery**

**Many IR devices are quite expensive – is this partially related to the small market base that they currently hold?**

If the market for a new technology is rather limited, the company does their own calculations in order to be viable. But if it turns out to be effective and its use can be increased, then the cost would also come down. And that could even be part of the performance-based agreements: if the technology can be more widely used than originally established, then there should also be a consequence for the price.

We have seen that with the coronary stents in the cardiovascular field. Initially it was not really clear to what extent the stents could take the market share of the balloon and market share of the bypass field. As the evidence base grew and stents became more popular, their cost started to decrease. You cannot ask a company to sell a technology for a loss, but you cannot tolerate that they ask prices that are not affordable by society. So it's a question of finding that happy medium. The happy medium is what health economics is all about!

C.M.



Health economics for non-economists is available to buy on Amazon, or directly from Academia Press

# Paediatric IR

## Tailor-made solutions for tiny patients

The smallest patients need special care, and that is precisely what paediatric interventional radiologists provide. Although a rare breed, there is great interest in this sub-specialty, with many children's hospitals offering a paediatric interventional radiology (IR) programme, or looking to begin one.

**IQ talks to Dr. Anne-Marie Cahill, director of the Paediatric IR programme in the Children's Hospital of Philadelphia, Pennsylvania, to find out what makes the specialty so unique.**

### How many children do you have coming through your centre?

*We do about 20-25 procedures a day, which is a huge volume. We're one of the largest in the US, with four paediatric interventional radiologists. Many of our patients have very specialised diseases, so they'll come from all over the country.*

### How many hospitals offer paediatric IR?

*Only the major children's hospitals offer this. There are probably only 10-15 of them in the US. In Europe, the big centre is Great Ormond Street Hospital in London.*

*Outside these centres, standard interventional radiologists may sometimes have to treat paediatric patients, as many places won't have a dedicated children's IR service within reach. However, the conditions and physiology of a paediatric patient are different from those of an adult and ideally, they should all be seen by specialist paediatric interventional radiologists.*

### Are all the procedures you use specific paediatric procedures?

*There is an overlap with the adult procedures, of course, but there are some children-only procedures we do – a common example is lumbar puncture: if babies get fever they have to test what the origin of the fever is. We'll use ultrasound to go into the spinal canal, because their bones aren't fully formed, so there is a window. You would never be able to do that in an adult.*

*But most of the procedures we do can also be used in adults, the main difference being the size: if it's a tiny access, like a small artery or vein, a standard IR might have to spend months with us learning how to get into these small vessels, small livers, small lungs, to do biopsies.*

### Is it difficult to find the right-sized equipment?

*It is: you need smaller needles, smaller access wires, little catheters that would be way too small for adults.*

*One company in particular has worked very closely with us to meet our needs, and we also use the smallest equipment of other companies, such as balloons for angioplasty or drainage catheters.*

*The calibration of the imaging equipment is also crucial – we see it all in one day, from premature babies to very large teenagers. The room must be set up to accommodate either, with X-ray equipment that's appropriate and monitoring devices that are smaller. You have to change your scope all day long.*

*The "adult" interventional radiologists don't have this to consider – patients might have varying degrees of illness, but their size-range is nowhere near as diverse. It's a completely different mindset – we always have to think about who's coming in next.*

### Are there any other challenges facing paediatric IR?


*A big challenge is protocol, particularly in oncology. The culture in paediatrics is a protective one. There's a sensitivity to doing research on children, and understandably, families are often reluctant to go off protocol or be randomised.*

*Additionally, it's hard to gather data: for example, the volume of malignant cancers that would allow us to do a prospective randomised trial is limited and there are rarely the numbers to run two arms of a trial. Even if there is a promising technique in the adult world, such as TACE, there usually isn't the data to support its use in children. So I think we paediatric interventional radiologists really need to get together and pool our data.*

**There is so much demand for our services, it's a unique profession**

### What kind of feedback do you tend to get from parents and patients? Do they ever have doubts about whether to go ahead with new procedures?

*Parents can be very nervous about allowing new therapies for their children. But when we do manage to recruit for a new procedure, for example, photodynamic therapy for neurofibromas, we have had promising results, and they're then more confident about enrolling for Phase II.*



**Children's Hospital of Philadelphia**  
The Children's Hospital of Philadelphia is the USA's oldest children's hospital, offering family-centred care. It is well known for its excellence and innovation, having been ranked "best pediatric hospital in the United States" by Parents magazine, as well as joint first in U.S. News & World Report's Honor Roll of the nation's Best Children's Hospitals.  
© The Children's Hospital of Philadelphia

Parents are often very grateful for what we do for their children, whether it's an everyday procedure or a life-saving treatment. They recognise you around the hospital and take the time to give you feedback. Families come back to us giving us hugs; the kids remembering the experience and telling us how much better they're feeling. It's a very sad situation when things do not go well, if a biopsy brings bad news, for example – but even then, many are grateful for that knowledge. There are lots of highs and lows in children's hospitals.

**How many paediatric interventional radiologists are there – is it a popular career choice?**

There certainly is interest: I personally have offered fellowship training for five years now, and we have fellows lined up for the next three years already, and others wanting to come. So, it's definitely rising in popularity but overall numbers are still low.

**Our patient volume is high enough that there is a budget for upgrades every few years**

**We have a good relationship with all of our referring physicians – it's one of the things that makes the hospital so successful**

Unless we are able to recruit sufficient people to provide the service, it will hinder the discipline, which would be a huge shame – there is so much demand for our services, it's a unique profession. Nobody can provide what we do – vascular surgeons rarely specialise in children, and paediatricians have a totally different skill set.

**Why is your hospital management happy to provide the IR department with state-of-the-art equipment?**

Our patient volume is high enough that there is a budget for upgrades every few years. We're very visible in the hospital: we offer an indispensable service.

The surgeons don't want to open up a liver when we can go in with catheters. There are things that only we can do in a minimally invasive way, such as vascular access, the PICC lines, the biopsies. And there are things that the surgeons would not be able to do if we were not there – there's a mutual respect. We have a good relationship with all of our referring physicians – it's one of the things that makes the hospital so successful.

C.M.



Patients at CHOP benefit from a family-oriented approach and receive their advanced therapies in welcoming surroundings.  
© The Children's Hospital of Philadelphia



# Trials and Registries

**Trial:** a study carried out with the purpose of testing a new medical treatment on a defined group of people. The results are compared with a group that are treated using another method and/or a control group.

**Registry:** a (retrospective) collection of data about a certain treatment or illness. Using the compiled data, conclusions can be drawn about effectiveness of a particular treatment method.

## Angioplasty

### Cutting Balloon versus Non-cutting Balloon for the Treatment of Venous Stenosis in the Fistulas of Hemodialyzed Patients (PREST)

#### Contact

Dr. Eric Picard, Centre Hospitalier Universitaire de Nîmes, FR

#### Date opened

September 2011

#### Status

Not yet recruiting

#### Description

The main objective of this study is to evaluate and compare the primary patency rate at 12 months in a group of haemodialysis patients operated on by cutting balloon and in a group of haemodialysis patients operated by conventional balloon.

**ClinicalTrials.gov Identifier:** NCT01321866

### Infrapopliteal Drug Eluting Angioplasty Versus Stenting (IDEAS-I)

#### Contact

Prof. Dimitrios Siablis, Patras University Hospital, GR

#### Date opened

August 2011

#### Status

Recruiting

#### Description

The study's primary endpoint will be the 6-month angiographic binary restenosis rate. Secondary endpoints will include the immediate technical success, 6-month primary patency, target lesion revascularisation and limb salvage and complication rates.

**ClinicalTrials.gov Identifier:** NCT01517997

### Moxy Drug Coated Balloon vs. Standard Balloon Angioplasty for the Treatment of Femoropopliteal Arteries (LEVANT 2)

#### Contact

Dr. Kenneth Rosenfield, Massachusetts General Hospital, US

#### Date opened

July 2011

#### Status

Recruiting

#### Description

The purpose of this study is to demonstrate the superior efficacy and non-inferior safety of the Moxy Drug Coated Balloon by direct comparison to standard PTA for treatment of stenosis of the femoropopliteal arteries.

**ClinicalTrials.gov Identifier:** NCT01412541

### Standard Balloon Angioplasty versus Angioplasty with a Paclitaxel-eluting Balloon for Femoral Artery In-stent Restenosis (FAIR)

#### Contact

Dr. Hans Krankenberg, Medical Care Center Prof. Mathey, Prof. Schofer, Ltd., DE

#### Date opened

January 2012

#### Status

Recruiting

#### Description

Comparison of recurrent-restenosis rates 6 months after angioplasty of in-stent restenoses or in-stent reocclusions in the superficial femoral artery (SFA) using either a standard balloon (Admiral Xtreme, Invatec) or a paclitaxel-eluting balloon (In.Pact™ Admiral, Invatec).

**ClinicalTrials.gov Identifier:** NCT01305070

## Carotid Stenting

### Effects of Cerebral Protection with Filters vs. Flow Reversal on Cerebral Embolization after Carotid Artery Stenting

#### Contact

Dr. Carlos H. Timaran, Dallas VA Medical Center, US

#### Date opened

October 2011

#### Status

Recruiting

#### Description

This study was designed to investigate whether balloon-based protection systems are more effective than filters in reducing the amount of particles that break off and travel to the brain during CAS.

**ClinicalTrials.gov Identifier:** NCT01414387



[www.intervention-iq.org](http://www.intervention-iq.org)  
[www.clinicaltrials.org](http://www.clinicaltrials.org)  
[www.cirse.org](http://www.cirse.org)  
[www.controlled-trials.com](http://www.controlled-trials.com)  
[www.who.int/trialsearch](http://www.who.int/trialsearch)  
<http://clinicaltrials.mayo.edu>



## Embolisation

### Balloon Catheters in Cases of Abnormal Placentation (Accreta)

**Contact**

Dr. Raed Salim, HaEmek Medical Center, IL

**Date opened**

January 2009

**Status**

Recruiting

**Description**

The objective of this study is to estimate the efficacy of balloon catheter interventions among women diagnosed with a placenta accreta.

**ClinicalTrials.gov Identifier:** NCT01373255

### Efficacy of Radiation Therapy and Transarterial Chemoembolization (TACE) to Treat Hepatocellular Carcinoma (HCC) (RTANDTACE)

**Contact**

Dr. Han Chu Lee, University of Ulsan College of Medicine, CN

**Date opened**

October 2011

**Status**

Recruiting

**Description**

In this study, the investigators are to prospectively evaluate patient's survival, tumour response, and safety of RT followed by TACE in patients with unilobar portal vein invasion.

**ClinicalTrials.gov Identifier:** NCT01432314

### Preoperative Embolization in Surgical Treatment of Spinal Metastases

**Contact**

Prof. Lars Lönn, Rigshospitalet, DK

**Date opened**

May 2011

**Status**

Recruiting

**Description**

The main purpose of this study is to assess the efficacy of preoperative embolisation in decreasing operative blood loss, decreasing the need for intraoperative transfusion and facilitate surgical resection in metastatic spine surgery.

**ClinicalTrials.gov Identifier:** NCT01365715

*Please note that this does not constitute an exhaustive overview of Trials and Registries. If you are aware of a Trial or Registry which may be of interest to our readers, please feel free to contact us at [info@intervention-iq.org](mailto:info@intervention-iq.org).*

*IQ takes no responsibility for the content of the individual trials; please refer to their Source for further information.*

### Transarterial Radioembolization versus Chemoembolization for the Treatment of Hepatocellular Carcinoma (HCC) (TRACE)

**Contact**

Prof. Luc Defreyne, University Hospital Ghent, BE

**Date opened**

September 2011

**Status**

Recruiting

**Description**

The objective is to prospectively compare TACE-DEB and 90Y-RE, two novel treatments that both show theoretical and/or proven advantages compared to the use of conventional TACE in patients with intermediate stage HCC.

**ClinicalTrials.gov Identifier:** NCT01381211

## Renal Denervation

### Efficacy and Safety of Radiofrequency Renal Denervation in Drug Resistant Hypertension

**Contact**

Dr. Stanislav Pekarskiy, Siberian Branch of the Russian Academy of Medical Sciences, RU

**Date opened**

March 2010

**Status**

Recruiting

**Description**

Single-centre, single group study of the efficacy and safety of transcatheter renal denervation for treatment of patients with essential hypertension uncontrolled despite combined pharmacotherapy including three or more hypotensive drugs one of which is a diuretic.

**ClinicalTrials.gov Identifier:** NCT01499810

## UAE/UFE

### Diffusion and Perfusion Weighted MRI for Response Prediction of Symptomatic Leiomyomas Following Uterine Artery Embolization

**Contact**

Prof. Geert Maleux, University Hospital Gasthuisberg, BE

**Date opened**

January 2012

**Status**

Recruiting

**Description**

It is known that volumetric response of leiomyomas following uterine artery embolisation correlates well with patients' clinical outcome. The aim of this study is to assess diffusion and perfusion weighted MRI for the prediction of volumetric response following uterine artery embolisation in patients with symptomatic leiomyomas.

**ClinicalTrials.gov Identifier:** NCT01514617

# The Early Days of IR



Many inventions result from eureka moments, but others unfold slowly over years of dedicated focus. The world's first optional filter was one such invention. IQ talks to its inventor, Prof. Rolf Günther, about his years of dedication and research.

*"When I started my training, interventional radiology (IR) barely existed. As I completed my training in 1975, the contours of therapeutic interventions were just appearing on the horizon. When I moved to Mainz University in 1972, the atmosphere was very inspiring, since we had great support from radiology, surgery and urology. Mainz University was well known for its angiographic focus at that time, having played host to Prof. Eberhard Zeitler's first diagnostic coronary angiography years earlier in the 1960s.*

*"We began to expand our diagnostic angiography experience, introducing new techniques and applications; new ways of accessing vessels and new ways of collaborating with other colleagues, such as developing percutaneous renal stone extraction together with our urologists.*

*"Initially my interest was primarily focused on the kidney and liver, and later on vascular interventions. During my time in Mainz and later on in Aachen, we experienced a fantastic flowering of IR and our highly motivated team made its small contribution by developing some new techniques and several interventional device patents. Almost obsessed by the idea of catheter-based minimally invasive interventions, we worked very hard clinically and experimentally day and night."*

In 1984, Prof. Günther took up the chairmanship of the Department of Diagnostic Radiology at the RWTH Aachen University, a university renowned for its technical innovation.



Günther Tulip™ Vena Cava Filter  
Permission for use granted by Cook Medical Incorporated,  
Bloomington Indiana

## Rolf W. Günther

"Inventor of the Günther Tulip™ Filter"

- 1971, began radiology training at the University of Heidelberg
- 1972-1975, continued education at Mainz University
- 1975-1984, Consultant/Associate Professor at Mainz University
- 1984-2010, Chairman of the Department of Diagnostic Radiology at the RWTH Aachen University
- 1989, Günther Tulip™ Filter (Cook Medical) launched
- 2010, Royal Hospital of Muscat/Oman
- 2011, Charité University Hospital in Berlin

*"For us radiologists, the strength of Aachen was not so much the technologically-driven atmosphere, but the recruitment of a great many highly motivated, innovative and skilled co-workers and the availability of an excellent animal laboratory for our experimental work.*

*"My activities were primarily clinically oriented, and I drew much inspiration from this. In order to improve research between IR and technical disciplines on a university level, we have recently established a formal long-term co-operation with one of my former consultants, Prof. Thomas Schmitz-Rode, now head of the Institute of Biomedical Technologies at RWTH Aachen University. This offers an interesting IR research infrastructure and long-term perspective for the future."*

Of course, what Prof. Günther is best known for is his innovative tulip filter – a breakthrough which overcame the limitations of previous filter designs.

*"The first caval filters in the late 1960s were simply too large. They were initially inserted by venotomy or later percutaneously via a large-calibre 24F sheath. After having observed the development of the percutaneous Simon nitinol and Bird's nest filters, we were looking for something better. Clinical need prompted us to develop a new "basket filter" in 1980, which primarily was not so successful because of fatigue fractures. Our research was also delayed by animal-rights activists hijacking the dogs we had placed the filters in. But by 1989, we had refined this basket design as the tulip filter, which was also suitable for retrieval. This was the first optional filter on the market."*

Despite his retirement in 2010, Prof. Günther continues his work in IR, and having spent some months at the Royal Hospital of Muscat, Oman, he is now working with Prof. Bernd Hamm at the Charité University Hospital in Berlin.

*With sincere thanks to Prof. Rolf W. Günther.*

C.M.

# What's in store

Coming up in Issue 7, September 2012

## Patient Safety and Interventional Radiology *Image-guided, minimally invasive medicine*

The dynamic field of interventional radiology (IR) is rapidly growing and is contributing to some of the most significant medical developments of our time. Many conditions can now be treated by IR, with reduced risk, pain, recovery time and hospital stay compared to conventional surgery.

IQ gives an exclusive behind-the-scenes look at the discipline and investigates how IR safeguards patient safety and treatment quality through education and professional competence.

To find out why hospital managers and patients are increasingly turning to their IR service for state-of-the-art, less invasive treatments, be sure to read September's IQ!



# Patient Safety and Interventional Radiology

## ... The Quarter's Focus

If you are interested in  
contributing to IQ,  
please contact  
[info@intervention-iq.org](mailto:info@intervention-iq.org)

Also featured:

- Hospital Managers' View
- Education & Training
- Quality Improvement

